

Abstract Type : Poster
Presentation No. : PGN 013

A case of proliferative glomerulonephritis with monoclonal IgG and light chain deposit simultaneously showing pathologic features of membranous and membranoproliferative glomerulonephritis

Jong Hwan Jung, Jee Eun Choi, Ju Hung Song, Seon-Ho Ahn
Department of Internal Medicine-Nephrology, Wonkwang University Hospital, Korea, Republic of

Introduction: Proliferative glomerulonephritis with monoclonal IgG disease (PGNMIGD) is a rare form of monoclonal gammopathy of renal significance. However, mechanism of the disease remains elusive. The pathological features of PGNMIGD are similar to those of membranoproliferative glomerulonephritis (MPGN) and membranous nephropathy (MN) with endocapillary proliferation. Most patients with PGNMIGD are older and have prominent proteinuria and renal insufficiency. We report a young patient of normal renal function with mild proteinuria whose final diagnosis was PGNMIGD showing both pathological features of MPGN and MN.

Case report: A 19-year-old male visited our clinic for evaluation of proteinuria incidentally detected. He had no any symptom and history. His serum creatinine and C3 were 0.72 and 85 mg/dL. Urine protein-creatinine ratio and albumin-creatinine ratio were 1280 and 640 mg/g. Serum and urine electrophoresis showed normal patterns. Serum free light chain analysis was within normal range. Angiotensin receptor blocker was prescribed. We underwent a renal biopsy due to persistent proteinuria. On pathologic results, mesangial matrix was increased with heavy immune deposits. Moreover, subepithelial humps and subendothelial deposit were scattered and foot processes showed focal marked effacement. On immunofluorescence findings, there were diffuse clumpy or globular mesangial stainings of several substances such as C3, C1q, IgG, and lambda.

Discussion: PGNMIGD is not a premyleomatous disease but an immune complex GN. PGNMIGD is expressed in the form of MPGN or MN in elderly patients and may present as progressive renal failure. However, PGNMIGD may present in younger patients and clinical manifestations may be minor, regardless of pathologic features. In conclusion, considering clinicopathological characteristics of PGNMIGD, the renal function of the patients with PGNMIGD combined with mild signs may be relatively deteriorated. Therefore, even in mild form patients with PGNMIGD showing both pathologic features of MPGN and MN, the use of immunosuppressants may need to be considered.

Figure 2. Immunofluorescence and electron microscopic findings show scattered mesangial IgG deposits and subepithelial hump and subendothelial deposits

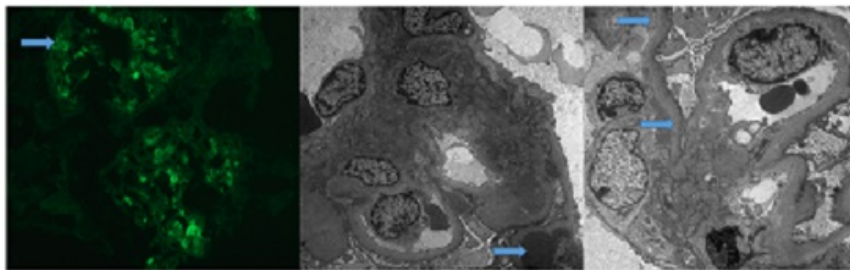


Figure 1. Light microscopic findings show mesangial proliferation and thickened glomerular basement membrane.

